

A comparison of two sphenoidotomy approaches using a novel computerized tomography grading system

Heitham Gheriani, F.R.C.S.C., F.R.C.S.I., David Flamer, B.Sc., Trent Orton, M.D., Brad Mechor, F.R.C.S.C., and Amin R. Javer, F.R.C.S.C.

ABSTRACT

Background: Endoscopic management of sphenoid sinus disease has great potential for surgical complications. A variety of endoscopic surgical techniques have been described for entering the sphenoid sinus. The utility of these surgical techniques is based on the position of the superior turbinate attachment to the sphenoid face (Parson's ridge). We introduce a novel computerized tomography (CT) grading system for the attachment of the superior turbinate to the sphenoid face. Using this new grading system, we recommend a safer systematic approach for entry into the sphenoid sinus.

Methods: A grading based on the attachment of the superior turbinate to the sphenoid face at the level of the natural sphenoid ostium was developed. A total of 53 patients were enrolled. Types A, B, and C refer to the superior turbinate attachment at the medial, middle, or lateral third of the anterior sphenoid face, respectively, and type D refers to orbital attachment of the superior turbinate. The surgical approach used (superior turbinate intact [STI] or superior turbinate resection [STR]) was recorded and correlated to the type of superior turbinate attachment.

Results: The overall incidence of the various superior turbinate attachments were 40% (41) for type A, 41% (42) for type B, 18% (19) for type C, and 1% (1) for type D. STR was used in 38 sides (44%) and STI was used in 48 sides (56%). Spearman correlation study showed that the closer the superior turbinate attachment was to the orbit the more likely STR was used as the choice of entry into the sphenoid ($p < 0.001$).

Conclusion: To perform a safe sphenoid entry it is pertinent to evaluate the superior turbinate attachment to the sphenoid face before making a decision on the method of entry.

(Am J Rhinol Allergy 23, 212–217, 2009; doi: 10.2500/ajra.2009.23.3249)

Key words: Bolger parallelogram, computerized tomography, functional endoscopic sinus surgery, Messerklinger technique, Parson's ridge, sphenoid face, sphenoid sinus, superior turbinate intact (STI), superior turbinate resection (STR), superior turbinate

The surgical approach to the sphenoid sinus continues to remain one of the challenges facing the endoscopic sinus surgeon. The main reason for this is the presence of important vital structures in the vicinity of a small space with the potential of a variety of anatomic variations. These vital structures include the optic nerve, III–VI cranial nerves, and the cavernous portion of the internal carotid artery. The consequences of damage to these vital structures can lead to a neurological disability, loss of vision or double vision, and even life-threatening hemorrhage.^{1–5} Historically, this topic has attracted a significant amount of attention from eminent surgeons and anatomists trying to identify surgically useful anatomic landmarks for safe entry into the sphenoid sinus. Van Alyea in 1941 published a study on examining the distance from the sphenoid ostium to the anterior nasal spine and found it to be around 58 mm. He recommended using a calibrated probe placed intranasally at a 23.5° angle above the hard palate and then checking the position of the probe using an x ray before performing a sphenoidotomy.⁶ Many recent authors have performed similar work with similar conclusions except for slight variations on the distance from the

sphenoid ostium and on the choice of the anterior fixed landmark; some have recommended the use of the nasal sill instead of the anterior nasal spine.⁷

With the introduction of endoscopic sinus surgery in the 1980s, improved definitions and safer surgical approaches to the sphenoid sinus started to emerge. The best choice of approach tends to vary depending on the experience of the surgeon, the presence of ethmoid disease or skull base tumor, or if the sphenoid sinus disease is isolated⁸ (Table 1). The sphenoid ostium has consistently been found medial to the superior turbinate attachment on the sphenoid face. This constant landmark has markedly helped the endoscopic sinus surgeon in identifying the sphenoid sinus and not confusing it with a large posterior ethmoid cell. Kim *et al.* reported that the sphenoid ostium can be found lateral to the superior turbinate attachment in ~17% of cases in a cadaveric dissection study published in 2001.⁷ This finding was challenged by Millar and Orlandi who found the sphenoid ostium medial to the superior turbinate attachment in a 100% of their 47 cadaveric specimens.⁹ They concluded that Kim *et al.* probably fractured and medialized some of the superior turbinates during mucosal stripping before dissection. In our experience we have never come across a single patient with the sphenoid ostium lateral to the superior turbinate attachment. The endoscopic entry to the sphenoid originally described by Stammberger, in his description of the Messerklinger technique, and later modified by many authors, including Bolger and Lanza, was by performing a partial resection of the superior turbinate through the superior meatus.¹⁰ Bolger *et al.* in 2001

From St. Paul's Sinus Center, St. Paul's Hospital, Vancouver, British Columbia, Canada

Address correspondence and reprint requests to Heitham Gheriani, F.R.C.S.C., Rhinology, Endoscopic Sinus and Skull base Surgery Fellow, St. Paul's Hospital, 2600 Providence Building, 1081 Burrard Street, Vancouver, BC V6Z 1Y6, Canada

E-mail address: gheriani@yahoo.com

Copyright © 2009, OceanSide Publications, Inc., U.S.A.

Table 1 Summary of different surgical approaches to the sphenoid sinus

Endoscopic transethmoidal either STR or STI	Commonly used in dealing with chronic rhinosinusitis and any associated sphenoid sinus disease, CSF leaks, or skull base tumors
Transseptal (endoscopic or microscopic)	Commonly used to approach sella tursica in case of pituitary tumors or sphenoid CSF leaks
Endoscopic transnasal (through superior meatus medial to superior turbinate)	Commonly used in isolated sphenoiditis, sphenoid abscess or tumors
Transnasal using the headlight	Mostly before development of endoscopic techniques
Transmaxillary	Used to approach lateral pathology of sphenoid sinus especially with intracranial extension
External approach through ethmoidectomy	Mostly before development of endoscopic techniques or for large skull base tumors
Transcranial external approaches (subfrontal, frontotemporal, and subtemporal)	Neurosurgical approaches
Sublabial	Used by neurosurgeons to approach pituitary tumors

CSF = cerebral spinal fluid; STI = superior turbinate intact; STR = superior turbinate resection.

described the “parallelogram” on the sphenoid face when dissecting through the posterior ethmoid: skull base superiorly, orbit lamina papyracea laterally, superior turbinate medially, and the superior turbinate basal lamella inferiorly.¹¹ They recommended that the point of entry into the sphenoid should be in the inferior medial half of the parallelogram and, preferably, with a gentle curette rather than forceful puncturing. This, they felt, would avoid a sharp instrument from sliding against the orbit and injuring the optic nerve or carotid artery along the lateral sphenoid wall. The main drawback with this method is that it does not take into account for variations of the superior turbinate attachment to the sphenoid face. A lateralized attachment would potentially leave a very small distance between the turbinate attachment and the orbit to allow for safe entry into the sphenoid, *i.e.*, it would significantly narrow the parallelogram. Using the parallelogram method for sphenoid entry in such a situation can result in injury to the vital lateral structures by entering very lateral into the sphenoid sinus. In extreme situations the superior turbinate can attach to the medial orbital wall leaving the sphenoid face completely within the sphenoid recess. In this situation, using the parallelogram (superior turbinate intact [STI]) technique can be extremely dangerous and an alternative approach (superior turbinate resection [STR]) to the sphenoid sinus should be utilized, *i.e.*, gentle resection of a small portion of the inferior part of superior turbinate using a through-cut instrument without disturbing the upper portion. The surgeon would then enter the sphenoid recess, identify the natural sphenoid ostium, and enlarge it in an inferomedial direction to gain entry into the sphenoid sinus. We use the term

STI technique when entering the sphenoid sinus from the posterior ethmoid using a parallelogram method and STR technique when entering *via* the sphenoid recess after resecting the inferior portion of the superior turbinate. Table 1 summarizes different surgical methods of entering the sphenoid sinus, some of which are now of historical interest.

MATERIALS AND METHODS

We used a novel computerized tomography (CT) classification system for the sphenoid face. The sphenoid face was divided into thirds in the axial plane at the level of sphenoid natural ostium. The standardized measuring plane was a line drawn on an axial cut at the level of sphenoid natural ostium from the nasal septum to the medial orbital wall laterally. We classified a side as type A if the superior turbinate attached the sphenoid face within the medial one-third, type B if the superior turbinate attached the sphenoid face in its middle one-third, type C if it attached to the lateral one-third, and type D if the superior turbinate attached directly to the orbit (Table 2 and Figs. 1–4).

After obtaining ethical approval, we analyzed preoperative axial and coronal CT scans of 53 consecutive patients (106 sides) undergoing endoscopic sinus surgery. We excluded all sides that had previous surgery to the sphenoid region.

During surgery the operating surgeon examined the axial and coronal CT and graded the sphenoid face using the sphenoid face grading system described previously. A decision was then made on the method of entry that would be the

Table 2 Classification of superior turbinate attachment to the sphenoid face

	Sphenoid Face Attachment			
	A	B	C	D
Superior turbinate attachment	Medial third	Middle third	Lateral third	Orbit

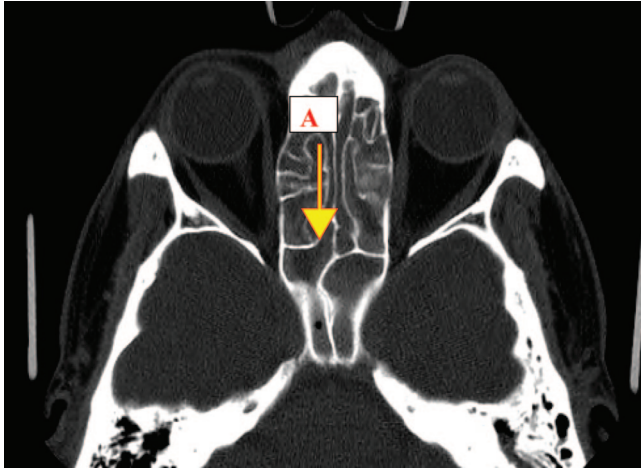


Figure 1. Axial computed tomography cut at the level of sphenoid natural ostium showing type A superior turbinate attachment.

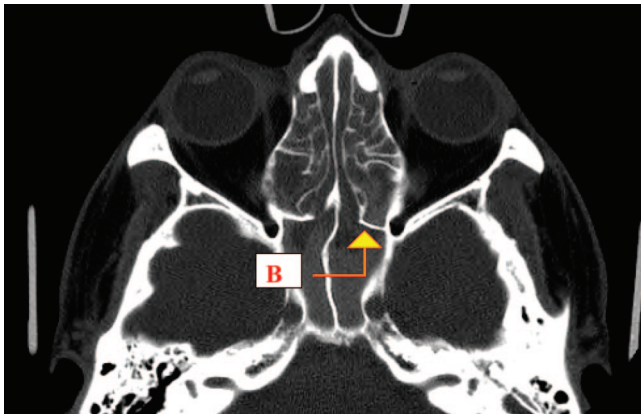


Figure 2. Axial computed tomography cut at the level of sphenoid natural ostium showing type B superior turbinate attachment.

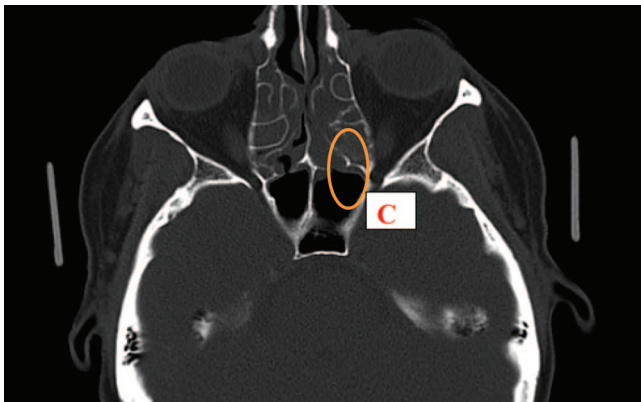


Figure 3. Axial computed tomography cut at the level of sphenoid natural ostium showing type C superior turbinate attachment.

safest after taking into account the type of sphenoid face and how close the superior turbinate attachment was to the orbit. Correlation was then made between the sphenoid face type and the actual method of entry utilized using Spearman rank

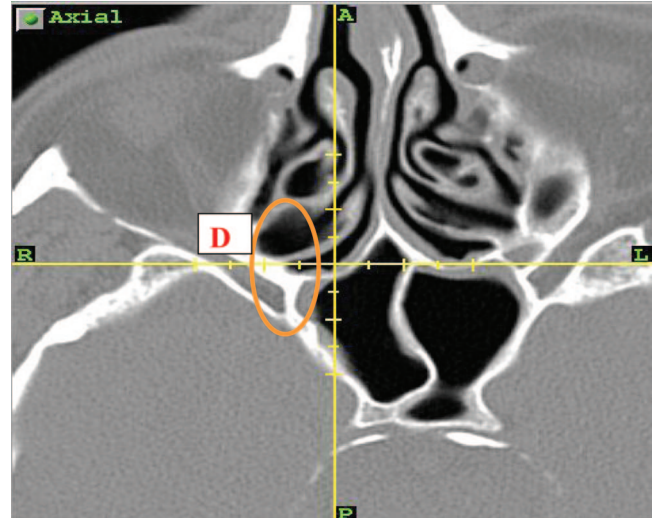


Figure 4. Axial computed tomography cut at the level of sphenoid natural ostium showing type D superior turbinate attachment.

order test. Statistical analysis of all data reported in this study was performed using SPSS 16.0 (SPSS, Inc., Chicago, IL).

RESULTS

Fifty-three patients were enrolled in the study. The mean age was 52 years (range, 16 -84 years) with 30 males patients (57%) and 23 (43%) female patients. There were no perioperative complications related to the surgery.

Sphenoid Face and Entry Type

Left Side (Table 3). All left sides of 53 patients enrolled were eligible for grading because the area of interest had no previous surgery.

Type A sphenoid face was the most common (22 sides or 41%) followed by type B (21 sides or 40%) and type C (10 sides or 19%). There was no type D found on the left side (0%).

Right Side (Table 4). Only 50 sides were eligible for the study. Three sides had had previous surgery in the sphenoid area and were excluded from the analysis. The results were as follows:

- Type A: 19 sides (38%)
- Type B: 21 sides (42%)
- Type C: 9 sides (18%)
- Type D: 1 side (2%)

Overall Incidence

The overall incidences of each superior turbinate attachment type for all sides put together were 40% (41) for type A, 41% (42) for type B, 18% (19) for type C, and 1% (1) for type D.

Entry Type

Left Side (Fig. 5). Entry into the sphenoid on the left side was required in 45 (85%) patients. The decision for entry was strictly clinical. The type of entry (STI versus STR) was determined by the surgeon based on the anatomy of the area. STI

Table 3 Summary of different types of sphenoid face on the left sides along with correlation to the choice of surgical approach

		Left Sphenoid Face Type			Total
		Type A	Type B	Type C	
Left side entry type	STR	2	8	8	18
	STI	18	9	0	27
	Total	20	17	8	45

		Value	Asymp. SE*	Approx. T#	Approx. Sig.
Ordinal by ordinal	Spearman correlation	-0.647	0.096	-5.559	0.000§
	no. of valid cases	45			

*Not assuming the null hypothesis.

#Using the asymptotic standard error assuming the null hypothesis.

§Based on normal approximation.

Table 4 Summary of different types of sphenoid face on the right sides along with correlation to the choice of surgical approach

		Right Sphenoid face type				Total
		Type A	Type B	Type C	Type D	
Right side entry type	STR	3	7	9	1	20
	STI	9	12	0	0	21
	Total	12	19	9	1	41

		Value	Asymp. SE*	Approx. T#	Approx. Sig.
Ordinal by ordinal	Spearman correlation	-0.525	0.119	-3.856	0.000§
	no. of valid cases	41			

*Not assuming the null hypothesis.

#Using the asymptotic standard error assuming the null hypothesis.

§Based on normal approximation.

technique was the most common and was used in 27 patients (60%) and STR was used in 18 patients (40%).

Right Side (Fig. 6). Entry into the sphenoid sinus on the right side was required in 41 patients (77%). Twenty-one patients (51%) required the STI technique and twenty patients (49%) required the STR technique.

Overall. STR as a surgical approach to the sphenoid was used 44% (38 patients) of the time while the STI approach was used 56% (48 patients) of the time.

Association between Sphenoid Type and Entry Method

Using the Spearman test, a statistically significant correlation was found between the sphenoid face type and the choice

of entry into the sphenoid on both sides, *i.e.*, the closer the sphenoid ostium to the orbit, the more likelihood of choosing the STR method of entry. A value of $p < 0.001$ was noted on both sides (see Tables 2 and 3 and Figs. 4 and 5).

DISCUSSION

Since the introduction of the Messerklinger technique in the 1980s¹² our understanding of the paranasal sinus anatomy and physiology has improved dramatically. This has been possible because of advancements in sinus surgical instrumentation, endoscope technology, image guidance, and increasing surgical experience. Transecting part of the superior turbinate to access the sphenoid sinus was part of the original description of the Messerklinger technique. Both Min *et al.* as

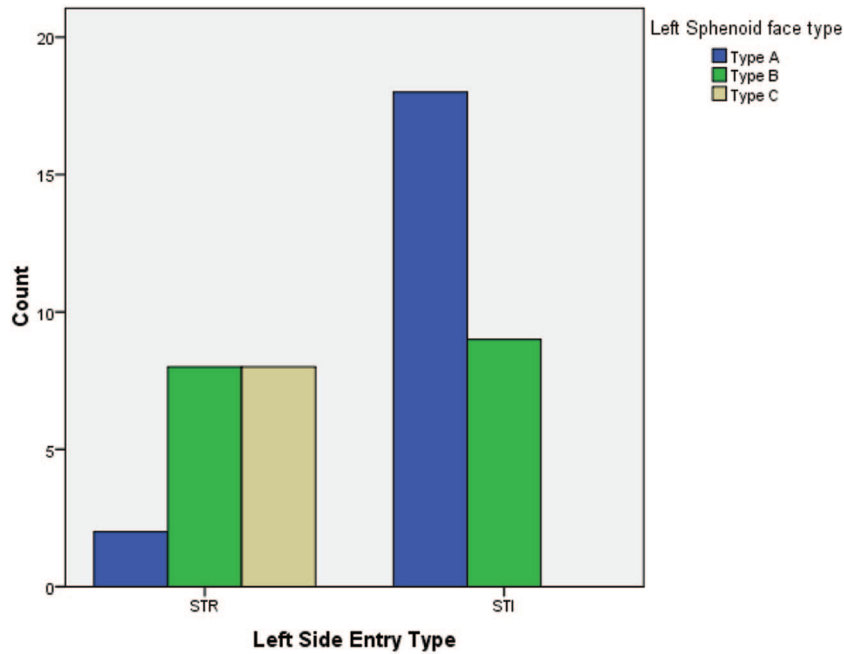


Figure 5. Bar chart comparing number of each superior turbinate attachment type versus type of entry on the left sides.

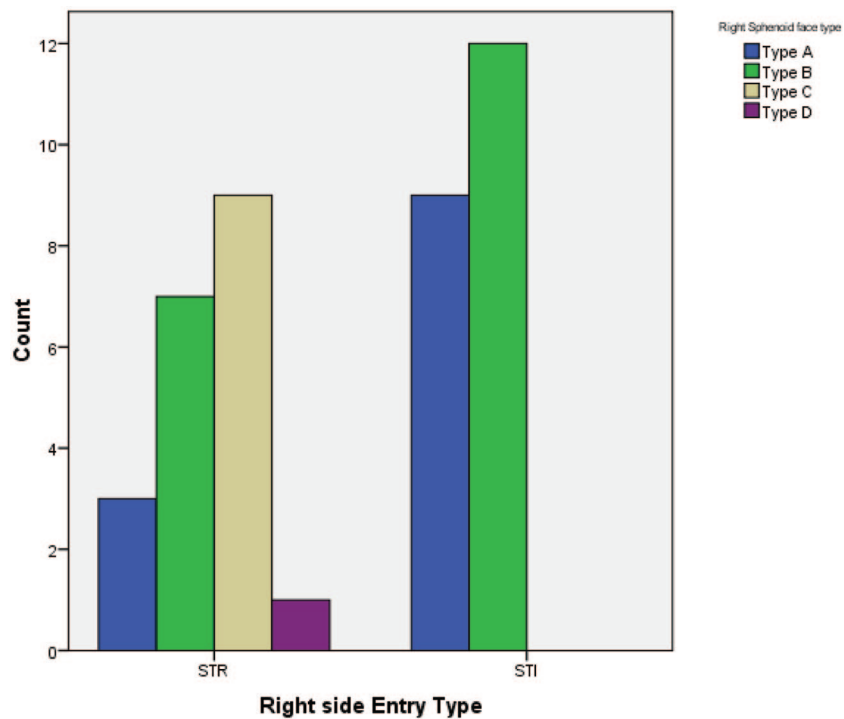


Figure 6. Bar chart comparing number of each superior turbinate attachment type versus type of entry on the right sides.

well as Metson *et al.* described complete amputation of the superior turbinate during the endoscopic approach to the sphenoid sinus to improve visualization and access.^{13,14} We feel that this is unnecessary and that every effort should be made to preserve both the middle and the superior turbinates when treating benign chronic sinus disease. Interfering with the vertical attachment of the superior turbinate to the skull base can risk olfaction as well as increase the risk of creating

a cerebral spinal fluid leak.¹⁵ The olfactory neuroepithelium is concentrated in the medial and superior part of the superior turbinate and trauma to the area adds to the risk of stripping and damaging this specialized mucosal covering. We feel that it is safer to use through-cutting instruments to remove a small portion of the inferior vertical superior turbinate in a type C or D attachments for entry into the sphenoid sinus *via* the natural ostium.

It is also important to consider the angle of attachment of the superior turbinate to the sphenoid face. An acute angle may result in a type A attachment superiorly and a type C attachment inferiorly on the sphenoid face. This is appreciated better on a coronal cut along the sphenoid face and can further aide in determining the proper technique of entry into the sphenoid sinus. Additional studies should be conducted on the prevalence and types of superior turbinate angulations. We strongly recommend that the surgeon correlate the axial and coronal CT cuts along the sphenoid face to determine the type and angle of attachment so that a safe decision can be made for entry into the sphenoid. A type C or D superior turbinate attachment should almost always favor an STR technique.

The principal objective of our study was to highlight the fact that a safe sphenoid entry method requires a careful assessment of the superior turbinate attachment to the sphenoid face on CT. We also wanted to introduce a novel grading system to allow for standardized terminology and technique. In the future, additional studies should be conducted, including testing for inter- and intraobserver variability to validate our grading system.

CONCLUSION

Careful assessment of preoperative axial and coronal CT scanning is essential for safe sphenoid entry. We recommend that the operating surgeon be aware of the type of superior turbinate attachment to the sphenoid face and the angle of the attachment before making a decision on the technique (STI versus STR) for entering the sphenoid sinus.

REFERENCES

1. Weidenbecher M, Huk WJ, and Iro H. Internal carotid artery injury during functional endoscopic sinus surgery and its management. *Eur Arch Otorhinolaryngol* 262:640–645, 2005.
2. Hollis LJ, McGlashan JA, Walsh RM, et al. Massive epistaxis following sphenoid sinus exploration. *J Laryngol Otol* 108:171–173, 1994.
3. Kadyrov NA, Friedman JA, Nichols DA, et al. Endovascular treatment of an internal carotid artery pseudoaneurysm following transsphenoidal surgery. Case report. *J Neurosurg* 96:624–627, 2002.
4. Pepper JP, Wadhwa AK, Tsai F, et al. Cavernous carotid injury during functional endoscopic sinus surgery: Case presentations and guidelines for optimal management. *Am J Rhinol* 21:105–109, 2007.
5. Koitschev A, Simon C, Löwenheim H, et al. Management and outcome after internal carotid artery laceration during surgery of the paranasal sinuses. *Acta Otolaryngol* 126:730–738, 2006.
6. Van Alyea O. Sphenoid sinus: Anatomic study, with consideration of the clinical significance of the structural characteristics of the sphenoid sinus. *Arch Otolaryngol* 34:225–253, 1941.
7. Kim HU, Kim SS, Kang SS, et al. Surgical anatomy of the natural ostium of the sphenoid sinus. *Laryngoscope* 111:1599–1602, 2001.
8. Gibbons MD, and Sillers MJ. Minimally invasive approaches to the sphenoid sinus. *Otolaryngol Head Neck Surg* 126:635–641, 2002.
9. Millar DA, and Orlandi RR. The sphenoid sinus natural ostium is consistently medial to the superior turbinate. *Am J Rhinol* 20:180–181, 2006.
10. Stammberger H. Endoscopic endonasal surgery concepts in treatment of recurring rhinosinusitis. Part II. Surgical technique. *Otolaryngol Head Neck Surg* 94:147–156, 1986.
11. Bolger WE, Keyes AS, and Lanza DC. Use of the superior meatus and superior turbinate in the endoscopic approach to the sphenoid sinus. *Otolaryngol Head Neck Surg* 120:308–313, 1999.
12. Stammberger H. Personal endoscopic operative technic for the lateral nasal wall. An endoscopic surgery concept in the treatment of inflammatory diseases of the paranasal sinuses. *Laryngol Rhinol Otol (Stuttg)* 64:559–566, 1985.
13. Min YG, Shin JS, and Lee CH. Trans-superior meatal approach to the sphenoid sinus. *ORL J Otorhinolaryngol Relat Spec* 1995 57:289–292, 1995.
14. Metson R, and Glicklich RE. Endoscopic treatment of sphenoid sinusitis. *Otolaryngol Head Neck Surg* 114:736–744, 1996.
15. Orlandi RR, Lanza DC, Bolger WE, et al. The forgotten turbinate: The role of the superior turbinate in endoscopic sinus surgery. *Am J Rhinol* 13:251–259, 1999. □

Copyright of American Journal of Rhinology & Allergy is the property of OceanSide Publications Inc. and its content may not be copied or emailed to multiple sites or posted to a listserv without the copyright holder's express written permission. However, users may print, download, or email articles for individual use.