

REVISION ENDOSCOPIC FRONTAL SINUSOTOMY WITH MUCOPERIOSTEAL FLAP ADVANCEMENT

The Frontal Sinus Rescue Procedure

Martin J. Citardi, MD, Amin R. Javer, MD,
and Frederick A. Kuhn, MD

Even after the widespread application of functional endoscopic sinus surgery principles, the management of chronic frontal sinusitis after previous sinus surgery remains among the most important and difficult surgical challenges. Revision endoscopic frontal sinusotomy must compensate for the greater tendency toward postoperative frontal ostium stenosis in patients who have had previous sinus surgery. As a result, further technical enhancements are necessary.

The role of middle turbinate sacrifice during endoscopic sinus surgery has engendered considerable controversy. Some authors have advocated routine middle turbinate resection; these surgeons propose that this technique decreases middle meatal scar formation and secondary maxillary antrostomy-ostium stenosis.² It is important to realize that these goals (namely functional patency of the middle meatus and the maxillary ostium) can be achieved routinely without middle turbinate removal. Gentle atraumatic technique and postoperative endoscopic debridements serve to create a functional middle meatus and maxillary sinus.

More importantly, middle turbinate sacrifice can create iatrogenic disease. In the frontal recess, middle turbinate resection has been associated

From the Department of Otolaryngology and Communicative Disorders, The Cleveland Clinic Foundation, Cleveland, Ohio (MJC); University of British Columbia, Vancouver, British Columbia, Canada (ARJ); and the Georgia Rhinology and Sinus Center, Savannah, Georgia (FAK)

with frontal sinus disease.¹⁴ After total middle turbinate resection, the frontal recess and internal frontal ostium may scar completely closed. Furthermore, the middle turbinate remnant that is created by subtotal resection typically lateralizes across the frontal recess to the medial orbital wall. In this situation, the frontal recess is separated from the rest of the nose, and the natural mucociliary outflow pathway is completely interrupted.

Standard endoscopic frontal sinusotomy was developed to take advantage of mucosa-lined rigid frontal recess walls. During this procedure, the thin frontal recess partitions of the anterior ethmoid cells are gently fractured with a 45- or 90-degree curette, which is maneuvered in a posterior to anterior direction under the visualization provided by a 30- or 70-degree telescope. Each of the resultant bony fragments are then removed with giraffe forceps, and all mucosa is conserved, especially in the vicinity of the frontal ostium. During standard frontal sinusotomy, the frontal ostium is not enlarged, and the bony boundaries of the frontal recess are not disrupted; rather, the anterior ethmoid partitions that can obstruct the frontal sinus drainage pathway in the frontal recess are atraumatically removed.

In the situation of frontal sinusitis after middle turbinate amputation, the bony middle turbinate remnant (i.e., the medial frontal recess wall) has been at least partially mobilized. In its lateralized position, this tiny bony fragment produces a bony stenosis of the frontal ostium. Standard endoscopic frontal sinusotomy cannot address this bony fragment and secondary frontal ostium stenosis.

Endoscopic frontal sinusotomy with mucoperiosteal flap advancement, a technique developed by the senior author (FAK), targets recurrent or persistent frontal sinusitis caused by frontal recess scar after middle turbinate amputation. This method, which we have termed *frontal sinus rescue procedure*, uses an endoscopic frontal sinusotomy and directly compensates for persistent middle turbinate lateralization and subsequent frontal ostium restenosis. The frontal sinus rescue procedure, which is much less aggressive than the modified endoscopic Lothrop procedure and frontal sinus obliteration, restores normal function to a diseased frontal sinus.

SURGICAL TECHNIQUE

The procedure is performed under general anesthesia or local anesthesia with intravenous sedation. At the beginning of the surgery, the nasal mucosa is decongested with topical 1% oxymetazoline. Additionally, 1% lidocaine with 1:100,000 epinephrine is infiltrated in the lateral nasal wall and in the frontal recess under endoscopic visualization.

Because the internal frontal ostium is typically located far anteriorly on the lateral roof of the nasal vault, the 30- and 70-degree telescopes must be used. The frontal recess is closely examined. Gentle palpation with a frontal seeker can be helpful. In these patients, the middle turbinate remnant is

displaced laterally across the frontal recess, as illustrated in Figure 1A. The bony remnant is typically encased in fibrous scar tissue.

A parasagittal incision is made with a sickle knife to release the soft tissue between the middle turbinate stub and the superior lateral nasal wall (Figs. 1B and 2). For adequate visualization, the sickle knife must be passed above the 30° or 70° telescope. At this point, a thin lamella of bone that actually is vertical middle turbinate remnant becomes apparent. A frontal seeker or a 90° frontal curette is used to elevate and preserve the frontal recess mucosa from the lateral aspect of this bony lamella (Fig. 1C). This mucosa is the mucoperiosteal advancement flap. Mucosa at the anterior nasal roof (medial to middle turbinate remnant) is removed to create a bed for the flap (Fig. 1D). The maxillary side-biting through-cutting forceps is used to remove the bony middle turbinate remnant up to the skull base

Rights were not granted to include this figure in electronic media. Please refer to the printed journal.

Figure 1. The frontal sinus rescue procedure. *A*, The frontal sinus (1) is separated completely from the nasal cavity by the middle turbinate stub (3), which is lateralized across the frontal sinus outflow tract. This adhesion is released by incising the area indicated by the arrow. *B*, After the adhesion is released, the frontal recess assumes this configuration. *C*, The mucosa on the lateral (2) and the medial (4) aspects on the bony middle turbinate stub (3) is elevated. *D*, The mucosa on the medial aspect (4) of the bony middle turbinate stub (3) is removed. *E*, The bony middle turbinate stub (3) is removed also. *F*, The mucoperiosteal flap (2) is draped medially. The curved arrow illustrates the natural drainage pattern for the frontal sinus. 1 = frontal sinus; 2 = mucoperiosteal flap (mucosa along the lateral aspect of the middle turbinate stub); 3 = bony middle turbinate stub; 4 = mucosa of the medial aspect of the middle turbinate stub; 5 = skull base at former bony middle turbinate insertion point. (From Kuhn FA, Javer A, Nagpal K, et al: The frontal sinus rescue procedure: Early experience and 3-year follow up. *American Journal of Rhinology* 14:211–216, 2000; with permission.)

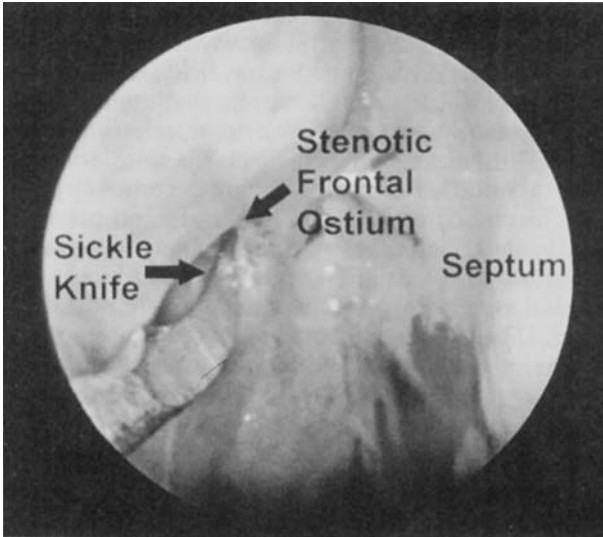


Figure 2. The sickle knife tip is located at the pinhole ostium of the right frontal sinus. Note the loss of all surgical landmarks, including the complete absence of the right middle turbinate.

(Fig. 1E). Visualization from below the maxillary side-biting forceps, which is placed so that its cutting surfaces face superiorly, is used to guide the instrument appropriately. Alternatively, a 90° frontal recess curette can be used to fracture the bony middle turbinate stub. All bony fragments are removed with the giraffe forceps. The mucosal flap is then advanced over the denuded area at the former insertion point of the middle turbinate (Figs. 1F and 3).

A stent may be used to hold the mucoperiosteal flap in position over the former middle turbinate insertion site. In most instances, this is not necessary, because the flap adheres over the denuded region medially, rather than the frontal ostium, which has not been traumatized. If a stent is used, the stent should fit loosely in the frontal ostium. A standard Pope earwick serves that purpose. Placement of the stent can be problematic, because its placement can push the flap into the frontal sinus and thereby void the entire purpose of the procedure. Large stents, which must be forced into the frontal sinus, must not be used.

Postoperative care includes serial nasal endoscopic examinations with gentle debridement of crusts, clot, and fibrin-filled debris. Patients are typically seen on the first postoperative day, on the seventh postoperative day, and then weekly or biweekly thereafter as needed. Prophylactic postoperative antibiotics are not routinely administered; all antibiotics are prescribed for culture-documented acute exacerbations of chronic rhinosinusitis. Systemic steroids are reserved for the treatment of sinonasal polyposis (usually in association with asthma) and allergic fungal sinusitis.

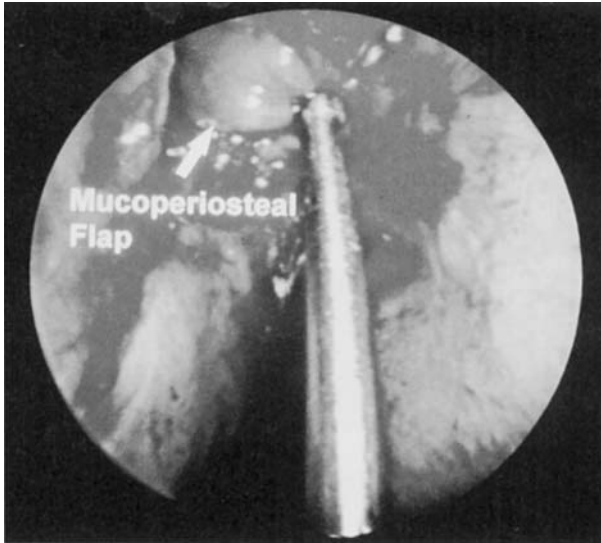


Figure 3. The frontal recess mucoperiosteal flap has been brought into position. The frontal seeker tip is at the most inferior and medial aspect of the flap.

RESULTS

Between July 1, 1996, and December 31, 1998, endoscopic frontal sinusotomy with mucoperiosteal flap advancement was performed on a total of 16 sides in 12 patients. Among the 16 sides on which the frontal sinus rescue procedure was completed, relief of frontal ostium stenosis and frontal recess scar was achieved for 14 frontal sinuses. The average duration of follow-up has been 8.5 months. The longest follow-up has been 30 months. Two patients have been lost to follow-up.

After the frontal sinus rescue procedure, the frontal ostium heals in a very characteristic pattern (Fig. 4). The procedure does not disrupt the mucosal integrity at the borders of the frontal ostium; as a result, postoperative stenosis is minimized. Serial nasal endoscopy confirms that mucociliary clearance has been restored.

Both surgical failures occurred in the same patient. Ethmoidal and frontal recess mucosal edema and early polypoid changes were noted in this patient within 2 weeks postoperatively; however, at 6 weeks postoperatively, each frontal ostium was patent. During the second 6-week postoperative period, frontal ostia shrunk to pinhole size, and bilateral frontal sinus rescue was performed a second time 3 months after the initial rescue procedures. (These secondary procedures are not included in this report.) Subsequently, the right frontal ostium has stayed patent, but the left frontal ostium has been narrowed by persistent edema. A third left revision endoscopic frontal sinusotomy with mucoperiosteal flap advancement was

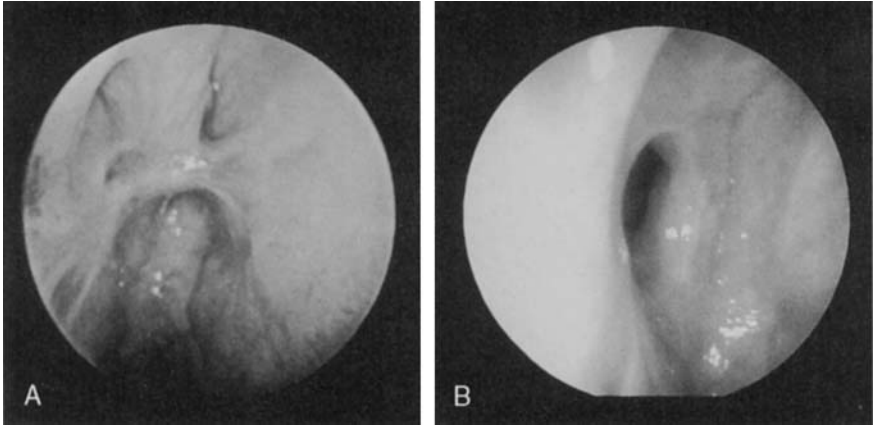


Figure 4. A, Preoperative nasal endoscopy, demonstrating complete right frontal ostium stenosis. B, Diagnostic nasal endoscopy 9 months after successful right frontal rescue procedure.

required, and that frontal sinus is now functioning normally. (This procedure is also not included in this report).

DISCUSSION

Although this is admittedly an early report, these preliminary results are encouraging in that most frontal sinuses have been spared more radical procedures, such as frontal sinus obliteration or endonasal drill-out. Each of these frontal sinuses now has a well-mucosalized, physiologic outflow tract, which is unlikely to develop restenosis.

These treatment successes may be attributed to certain features that are intrinsic to revision endoscopic frontal sinusotomy with mucoperiosteal flap advancement:

- The local advancement flap interrupts the geometry of the circumferential scar.
- The medial bony frontal recess stenosis is removed.
- The frontal recess opening is changed to nearly vertical orientation from a horizontal orientation.
- The important lateral frontal recess mucosa, which sweeps mucus out of the frontal sinus, is preserved.
- Frontal sinus mucociliary clearance is restored.

Historical Background and Fundamental Principles

In the 1920s, Lynch⁹ described the external frontoethmoidectomy procedure. During this time, many surgeons recognized the importance of restenosis of the frontal recess as a cause of surgical failure. To minimize

this problem, Sewall^{12,13} reported, in 1935, the use of mucoperiosteal flap from the anterior lateral nasal wall to reline a surgically enlarged frontal opening. In 1936, McNaught¹⁰ described a similar procedure. Boyden^{3,4} later wrote extensively about Sewall's procedure.

Even in the early part of this century, sinus surgeons recognized the role of postoperative frontal recess–ostium scar in the development of persistent or iatrogenic chronic frontal sinusitis. These procedures hold important lessons for surgeons even in the era of functional endoscopic sinus surgery:

- Mucosal preservation is paramount.
- The removal of mucosa from the internal frontal ostium inevitably leads to postoperative scarring and obstruction.
- Mucosal flaps can be created, manipulated, and advanced in the frontal recess.

The endoscopic frontal sinus rescue procedure builds on these concepts. The fundamental issue in the management of chronic frontal sinusitis after middle turbinate resection is frontal ostium stenosis or even complete closure. Procedures that merely create a hole at the frontal ostium into the frontal sinus inevitably destroy frontal recess mucosa, leading to circumferential scarring and frontal ostium closure. These procedures also tend to sacrifice lateral frontal recess mucosa that is essential for normal mucociliary clearance of the frontal sinus.

Indications

The frontal sinus rescue procedure is indicated for the management of refractory chronic frontal sinusitis after partial or total middle turbinate resection. Other conditions, such as bone erosion, frontal sinus osteitis or osteoneogenesis, frontal sinus mucocele, and frontal bone osteomyelitis, may also be present.

Revision endoscopic frontal sinusotomy with mucoperiosteal flap advancement also may be used for the definitive management of frontal sinusitis associated with an intracranial complication after the initial management, which usually includes intravenous antibiotics, trephination, and craniotomy. Furthermore, the frontal sinus rescue procedure also may play a role in the management of frontal sinus–recess tumors, including osteoma, and frontal sinus fractures.

Contraindications

Patients whose middle turbinates are intact should not undergo the frontal sinus rescue procedure. Standard endoscopic frontal sinusotomy is the indicated approach for refractory chronic frontal sinusitis in this group.

Frontal sinus rescue is not intended for the treatment of acute frontal sinusitis, or active osteomyelitis that has not been treated adequately with intravenous antibiotics.

Surgical Options for Chronic Frontal Sinusitis after Middle Turbinate Resection

For the patient who presents with chronic frontal sinusitis after middle turbinate sacrifice, treatment options are limited. Before any sinus surgery, maximal medical management should be instituted; however, in the setting of previous middle turbinate amputation, chronic frontal sinusitis is likely caused by anatomic obstruction of the frontal sinus outflow tract, and definitive relief of this anatomic problem is typically required. Both frontal sinus obliteration and the modified endoscopic Lothrop procedure may be considered; however, each of these procedures entails significant morbidity.

Frontal sinus obliteration with autogenous fat was introduced and popularized during the 1950s and 1960s.⁵ This major surgical procedure has been the subject of several major reports.^{7,11} Nonetheless, frontal sinus obliteration has several limitations, including perioperative morbidity, chronic pain, and delayed mucocele formation. In addition, evaluation of possible recurrent frontal sinusitis is at best problematic and usually impossible, even with the use of advanced imaging techniques.⁸ Furthermore, frontal sinus obliteration is focused on the contents of the frontal sinus, whereas the underlying pathophysiology in frontal sinusitis is obstruction at the frontal ostium and recess. Sinus obliteration destroys a potentially functional frontal sinus at the cost of significant morbidity.

More recently, the modified endoscopic Lothrop procedure, which encompasses transnasal drill-out of the frontal sinus floor under endoscopic visualization, has been described.^{1,6} Because chronic frontal sinusitis after middle turbinate sacrifice is caused by frontal recess stenosis by middle turbinate remnant lateralization and circumferential soft tissue scar formation, proponents of this surgery advise that the modified Lothrop procedure is an alternative to frontal sinus obliteration. Although this is an endoscopic technique, it cannot be considered minimally invasive because the drill-out destroys the frontal recess, the anterior superior septum, and adjacent mucosa. After this surgery, frontal sinus mucus may not drain, because the restenosis develops in the heavily traumatized frontal recess. In addition, even if the frontal neo-ostium contracture is only mild to moderate, mucus still may not drain, because the natural frontal sinus and frontal recess mucociliary clearance has been irretrievably altered. The long-term impact of this loss of nasal structures is unknown. The original Lothrop procedure, as reported in the early twentieth century, fell into disuse shortly after its initial description. In sum, the modified Lothrop is radical surgery that is not based on known principles of paranasal sinus physiology.

The revision endoscopic frontal sinusotomy with mucoperiosteal flap advancement is a minimally invasive, endoscopic alternative that is based on established physiologic principles. The natural mucociliary clearance of the frontal sinus is directed from lateral to medial over the orbit, and normally involves some recirculation in that some mucus travels from the frontal ostium superiorly along the frontal intersinus septum. Any

surgical procedure that disrupts the normal mucociliary clearance tends to promote mucus stagnation and resultant infection. The frontal sinus rescue procedure seeks to restore this normal frontal sinus physiology, whereas the modified Lothrop destroys frontal recess mucosa and alters mucociliary clearance, potentially causing recurrent chronic frontal sinusitis.

Advantages

The endoscopic frontal sinus rescue procedure, incorporating a mucoperiosteal flap, for surgical correction of frontal ostium obstruction after middle turbinate sacrifice offers several advantages:

- The opening into the frontal sinus typically remucosalizes without scar formation, granulation tissue growth, and restenosis.
- The flap is oriented such that the natural mucociliary clearance of the frontal sinus is actually restored and not disrupted.
- The procedure is a natural extension of endoscopic frontal sinusotomy and traditional external ethmoidectomy approaches.
- The procedure is less invasive than frontal sinus obliteration.
- The procedure is much less destructive than frontal sinus drill-out procedures.
- Additional surgical revision, if necessary, can be performed easily.

Disadvantages

The frontal sinus rescue procedure has several disadvantages:

- Although overall visualization is excellent, the entire procedure is performed using the 30- and 70-degree telescopes.
- Further advances in endoscopic instrumentation are needed.
- The flap itself is delicate and easily injured during the procedure.
- The operation is technically challenging, and the operating surgeon must be comfortable with advanced endoscopic approaches to the frontal sinuses.
- Because the operative site is in close proximity to the lateral lamella of the cribriform plate (thinnest part of the skull base), the potential risk of a cerebrospinal fluid leak must not be discounted.

SUMMARY

Chronic frontal sinusitis caused by frontal recess scarring and internal frontal ostium stenosis after middle turbinate sacrifice remains an important surgical challenge, even in the age of functional endoscopic sinus surgery. Revision endoscopic frontal sinusotomy with mucoperiosteal flap advancement, which we have called "the frontal sinus rescue procedure," attempts to prevent restenosis of the frontal recess and internal frontal ostium. By draping the flap across the raw edges, the amount of scarring and

granulation tissue is lessened. In this way, patients may be spared radical frontal sinus surgery, such as frontal sinus obliteration and the modified endoscopic Lothrop procedure, and instead be offered an endoscopic solution to an iatrogenic problem.

References

1. Becker DG, Moore D, Lindsey WH, et al: Modified transnasal endoscopic Lothrop procedure: Further considerations. *Laryngoscope* 105:1161, 1995
2. Biedlingmaier JF: Endoscopic sinus surgery with middle turbinate resection: Results and complications. *Ear Nose Throat J* 72:351, 1993
3. Boyden GL: Chronic frontal sinusitis: End results of surgical treatment. *Trans Am Acad Ophthal Otolaryngol* 61:588, 1957
4. Boyden GL: Surgical treatment of chronic frontal sinusitis. *Ann Otol Rhinol Laryngol* 61:558, 1952
5. Goodale RL, Montgomery WW: Experiences with osteoplastic anterior wall approach to frontal sinuses. *Arch Otolaryngol* 68:271, 1958
6. Gross WE, Gross CW, Becker DG, et al: Modified transnasal endoscopic Lothrop procedure as an alternative to frontal sinus obliteration. *Otolaryngol Head Neck Surg* 113:427, 1996
7. Hardy JM, Montgomery WW: Osteoplastic frontal sinusotomy, an analysis of 250 operations. *Ann Otol Rhinol Laryngol* 85:523, 1976
8. Loevner LA, Yousem DM, Lanza DC, et al: MR evaluation of frontal sinus osteoplastic flaps with autogenous fat grafts. *AJNR Am J Neuroradiol* 16:1721, 1995
9. Lynch RC: The technique of a radical frontal sinus operation which has given me the best results. *Laryngoscope* 31:1, 1921
10. McNaught RC: A refinement of the external frontoethmoidal operation: A new nasofrontal pedicle flap. *Arch Otolaryngol* 23:544, 1936
11. Sessions RB, Alford BR, Stratton C, et al: Current concepts of frontal sinus surgery: An appraisal of the osteoplastic flap-fat obliteration operation. *Laryngoscope* 82:918, 1972
12. Sewall EC: External operation of the ethmoidal-frontal group of sinuses under local anesthesia, technique for removal of part of optic foramen wall for relief of pressure on optic nerve. *Arch Otolaryngol* 4:377, 1926
13. Sewall EC: The operative treatment of nasal sinus disease. *Ann Otol Rhinol Laryngol* 44:307, 1935
14. Swanson PB, Lanza DC, Vining EM, et al: The effect of middle turbinate resection upon the frontal sinus. *Am J Rhinol* 9:191, 1995

Address reprint requests to

Martin J. Citardi, MD
 Department of Otolaryngology and Communicative Disorders
 The Cleveland Clinic Foundation
 9506 Euclid Avenue, Desk A71
 Cleveland, OH 44195