

# The safety and performance of a maxillary sinus ostium self-dilation device: a pilot study

Iain Hathorn, MBChB, FRCSEd (ORL-HNS), Al-Rahim Habib, MSc, Rachele Dar Santos, BSc, CCRP and Amin Javer, MD, FRCSC

**Background:** Balloon dilation is now commonly used to open sinus ostia while preserving mucosa and minimizing trauma. A new maxillary sinus ostium (MSO) self-dilation device that functions on the principle of osmosis, absorbing a small amount of fluid from the surrounding tissues, can be placed into the MSO under endoscopic visualization and slowly enlarge its outer diameter. The slower dilation may further minimize tissue damage and scarring compared to the currently available balloon dilation systems. The MSO self-dilating expansion device has never been studied before in clinical trials; the purpose of this pilot study is to determine the safety and performance of the device in human subjects.

**Methods:** Twelve chronic rhinosinusitis (CRS) patients presenting with maxillary sinus inflammation requiring FESS were enrolled. The device was inserted into the MSO at the start of surgery and removed after 60 minutes. Endoscopic evaluation for patency was performed immediately after removal, and at 1 week, 1 month, and 3 months. Adverse events were recorded intraoperatively and at each subsequent visit.

**Results:** The device was successfully inserted in 100% of cases attempted (19/19 MSOs, 12 patients). Seventeen (89%) devices remained in the MSO for 60 minutes and dilated to a mean diameter of  $4.8 \pm 0.5$  mm. One patient was withdrawn from the study. No adverse events occurred during insertion or removal of the device. At 3 months postinsertion 14 of 15 MSO dilated (93%) were confirmed patent.

**Conclusion:** Placement of an osmotic self-dilating expansion device in human MSO is safe, achievable and effective at dilating the ostia. © 2014 ARS-AAOA, LLC.

**Key Words:**

chronic rhinosinusitis; maxillary sinusitis; dilatation; feasibility studies; balloon; device

**How to Cite this Article:**

Hathorn I, Habib A-R, Dar Santos R, Javer A. The safety and performance of a maxillary sinus ostium self-dilation device: a pilot study. *Int Forum Allergy Rhinol.* 2014;4: 625-631.

Chronic rhinosinusitis (CRS) is a significant health problem.<sup>1,2</sup> In patients with CRS the maxillary sinus is frequently affected and contributes significantly to the impact of the disease, making it a target for medical and surgical intervention. Treatment of CRS involves medical and surgical treatment or often a combination of the two. The most frequently used surgical approach is functional endoscopic sinus surgery (FESS), which aims to open up the sinus drainage pathways and enhance mucosal

clearance.<sup>3</sup> Surgery can be directed at relieving obstruction and occasionally enlarging the maxillary sinus ostium (MSO), which is routinely performed as part of FESS. FESS is typically performed under general anesthesia and may result in scarring and adhesions postoperatively. It has been suggested that a small middle meatal antrostomy with less tissue removal and preservation of normal structures might be as effective as a large one.<sup>4</sup> This has encouraged alternative approaches to enlarge the sinus ostia including balloon catheter technology.<sup>5</sup> Balloon dilation is now commonly used to open sinus ostia while preserving mucosa and minimizing trauma. It has been shown to be effective for the treatment of obstructed sinus ostia in CRS,<sup>6-8</sup> and may reduce postoperative scarring and stenosis. Balloon technology is constantly developing and is now being used routinely in the office under local anesthesia.<sup>9</sup>

There is a new maxillary sinus ostium self-dilation device (Vent-Os™ Sinus Dilation System, SinuSys Corporation, Palo Alto, CA) that functions on the principle of osmosis,

St. Paul's Sinus Centre, St. Paul's Hospital, Vancouver, BC, Canada

Correspondence to: Iain Hathorn, MBChB, FRCSEd (ORL-HNS), St. Paul's Sinus Centre, St. Paul's Hospital, 1081 Burrard Street, Vancouver, BC V6Z 1Y6, Canada; e-mail: iainhathorn@hotmail.com

Funding sources for the study: SinuSys Corporation.

Potential conflict of interest: None provided.

Received: 19 December 2013; Revised: 30 March 2014; Accepted: 11 April 2014

DOI: 10.1002/alr.21343

View this article online at [wileyonlinelibrary.com](http://wileyonlinelibrary.com).

absorbing a small amount of fluid from the surrounding tissues. It can be placed into the maxillary sinus ostium under endoscopic visualization and is able to slowly enlarge its outer diameter under low pressure (42 psi) to a pre-determined dimension. Slow, low pressure dilation of the maxillary sinus ostia is expected to minimize tissue damage and potentially reduce scarring.

The new self-dilation device has been studied prior to this clinical trial in bench testing, cadaver and animal studies.<sup>10</sup> A total of 13 sheep (26 maxillary sinuses) had a dilation device placed in each of the MSO. Placements were performed under endoscopic visualization with the animals under general anesthesia. The studies showed that the devices were capable of dilating and enlarging the MSO. The diameter of the enlarged ostia measured immediately after removal of the device was very similar to the outer diameter of the device after removal. In 4 animals an endoscopy with measurement of the MSO was performed approximately 2 weeks and 4 weeks after the procedure and showed patency of the MSO with no significant alteration of the diameter.

This is the first clinical trial to evaluate the self-dilation device. This pilot study concentrated on the placement, functionality, and removal of the device with the primary objective of assessing the safety and performance of the system for dilation of the MSO.

## Patients and methods

This is a single-center, pilot, open-labeled prospective study. It was conducted with the approval of the University of British Columbia Clinical Research Ethics Board. Patients aged 19 to 75 years inclusive, with a diagnosis of chronic maxillary sinusitis (according to the Canadian Clinical Practice Guidelines for Acute and Chronic Rhinosinusitis) who failed medical management (including topical steroids and antibiotics) and were due to undergo endoscopic sinus surgery were eligible to be enrolled in the study (Fig. 1). The subjects that participated signed a consent form and an endoscopic assessment of the MSO was made preoperatively to assess patency. Preoperative computed tomography (CT) scans were performed in all cases to establish paranasal sinus anatomy and to assess the extent of sinus disease as is standard practice. They had a dilation device placed in 1 or both MSO intraoperatively under direct endoscopic visualization. If other endoscopic sinus surgery was required, it was performed (eg, ethmoidectomy) with the device in situ. Other surgery performed in each case is documented in Table 1. The device was placed at the beginning of surgery with the ethmoid bulla intact and no uncinectomy was performed. The device was left in the MSO for 1 hour to allow it to dilate, after which it was removed using standard endoscopic surgical instruments under direct endoscopic visualization. Standardized photographs and videos were taken immediately after removal to assess the MSO. Patency of the MSO immediately after dilation was recorded.

The inclusion criteria included:

1. Age  $\geq 19$  and  $\leq 75$  years.
2. Diagnosis of chronic maxillary sinusitis.
3. Subject is scheduled for endoscopic sinus surgery.

The exclusion criteria included:

1. Subject has one of the following diagnoses: cystic fibrosis, aspirin sensitivity, steroid dependent asthma, nasal polyposis, sinonasal tumors, allergic fungal sinusitis, ciliary dysfunction, perforated septum, atrophic nasal mucosa, excessive osteogenesis.
2. Any anatomic abnormality that precludes access to the maxillary sinus ostium (e.g. deviated septum).
3. History of facial trauma that resulted in distortion of the nasal and/or sinus anatomy
4. Previous middle meatal antrostomy.
5. Clinical evidence of acute respiratory or sinus infection requiring antibiotic or antifungal treatment 1 week before the procedure
6. Diagnosis of hematologic diseases, bleeding diathesis
7. Subject has a known infection with human immunodeficiency virus, other immune deficiency, insulin dependent diabetes or other serious systemic disease.

FIGURE 1. Inclusion and exclusion criteria.

The outcome measures were as follows:

- Safety as evidenced by an assessment of the adverse events related to MSO dilation procedure;
- Efficacy defined by patency of MSO immediately after removal of the dilation device;
- Reports of sinus related adverse events during the 3 months follow-up period.

The subjects were followed-up at 1 week, 1 month, and 3 months after MSO dilation. Postoperatively they were given a 1-week course of oral prednisolone (10 mg OD) and antibiotics (co-amoxiclav), along with regular nasal douches (saline with a single budesonide respule), as is standard practice at our institution following sinus surgery. During the follow-up period if subjects received any other medication, such as topical budesonide spray, this was recorded. At each follow-up visit and preoperatively, rigid nasal endoscopy with a 30-degree and 70-degree endoscope was performed and standard photographs and videos were taken. The patency of the MSO and any adverse events were recorded at each visit.

This was a pilot study designed to provide preliminary observations and generate safety and feasibility data to guide future studies. The sample size was selected to meet the goals of this feasibility clinical trial. Descriptive statistics were used for continuous variables and for categorical variables.

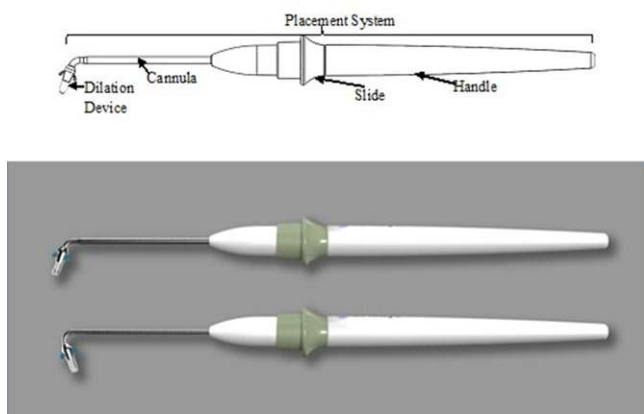
## Device and placement

The dilation system is an osmotically driven dilation device and comes packaged with the dilation device preloaded in the distal tip of the cannula of the placement system (Fig. 2). The dilation device was delivered under endoscopic

**TABLE 1.** Subject demographics and characteristics

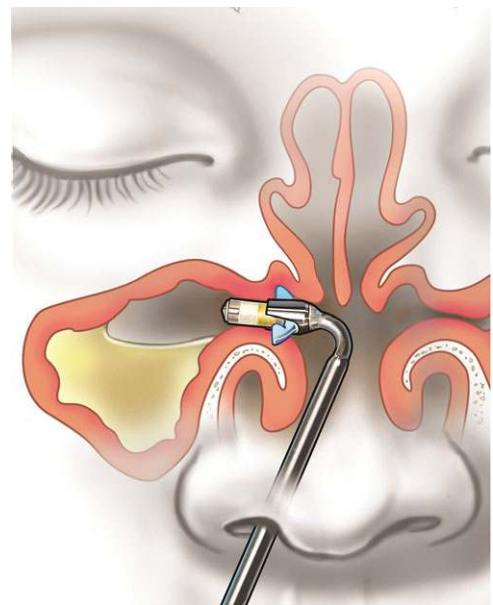
Subject	Age (years)	Sex	Bilateral Lund-Mackay score	Side of insertion	Additional procedures
1	53	F	1	R, L	U (R)
2	53	F	2	L	U (R), CB (L)
3	47	M	4	R, L	E (R, L), NS
4	69	F	14	R, L	U (R), E (R, L), S (L), F (R, L)
5	75	M	4	R, L	CB (R, L)
6	41	F	6	R	U (L), E (L), F (L)
7	20	M	10	R, L - dislodged	U (L), E (R, L), S (R, L), F (R, L)
8	47	M	16	R - removed, L	U (R), E (R, L), S (R, L), F (R), CB (L)
9	70	F	9	R, L	E (R, L) S (L), F (L), CB (L)
10	43	M	8	R	U (L), E (R, L), F (L), CB (R, L), NS
11	60	M	8	R	U (L), E (R, L), S (R, L), F (L), NS
12	20	F	6	L	U (R)

CB = excision of concha bullosa; E = ethmoidectomy; F = frontal sinusotomy; NS = nasal septoplasty; S = sphenoidotomy; U = uncinectomy.



**FIGURE 2.** Vent-Os™ Sinus Dilation System, SinuSys Corp, Palo Alto, CA.

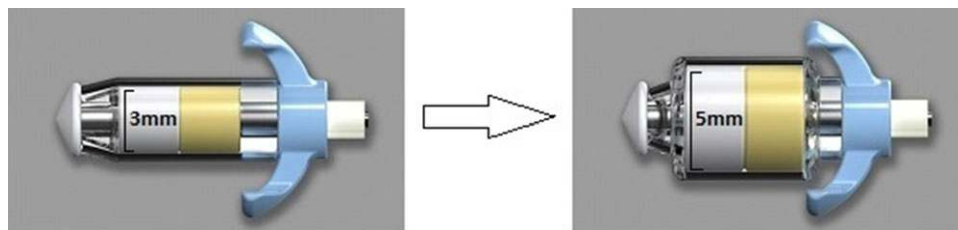
guidance via the placement system to the ostium of the maxillary sinus (Fig. 3). All device insertions were conducted intraoperatively under general anesthesia by the senior author (A.R.J.). Once the dilation device was in place, it was released by sliding the slider forward and the placement system was removed. The device then dilated expanding the ostium over a period of time (up to 1 hour) by absorbing a small amount of fluid from the surrounding tissues (Fig. 4). The dilation device was then removed from the ostium. There were 70-degree and 110-degree angled systems available to allow placement of the device. Prior to insertion, the device is approximately 3 mm in diameter and is designed to expand to nearly 5 mm after 60 minutes. Insertion devices were measured before and after each insertion.



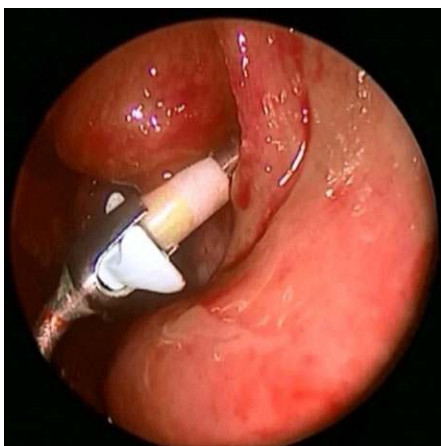
**FIGURE 3.** Dilation device placed under endoscopic guidance into the ostium of the maxillary sinus.

## Results

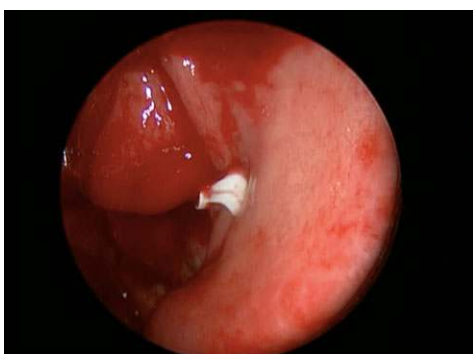
Between May 2012 and January 2013, a total of 14 adults were approached to participate into this prospective, nonrandomized, single-cohort clinical trial. Of those approached, 2 (14%) were excluded as they did not meet the inclusion criteria. The final cohort consisted of 12 individuals with equal distribution of males and females (Table 1). The mean age of the final group was  $51.5 \pm 17.8$  years. Among those included, a total of 19 MSO were evaluated to receive insertion of the experimental device.



**FIGURE 4.** Osmotic self-dilating expansion device.



**FIGURE 5.** Insertion of device to left maxillary sinus ostium.



**FIGURE 6.** Device in position in left maxillary sinus ostium during FESS. One arm of the device is shown on top of the uuncinate holding it in place. FESS = functional endoscopic sinus surgery.

This consisted of 10 (53%) right and 9 (47%) left MSO. All MSO were assessed endoscopically prior to surgery but it was not possible to measure the maxillary sinus ostia size due to the presence of the uuncinate and inflammation obstructing the MSO. MSO patency was evaluated from the preoperative CT scans. Eleven (58%) MSOs were obstructed and 8 (42%) were narrowed to less than 2.5 mm. All maxillary sinuses had signs and radiographic evidence of maxillary CRS. The device was successfully placed into the MSO in 19 (100%) cases (Figs. 5 and 6). The uuncinate process remained intact during the placement of the device in all cases. There were no adverse events reported during placement. The device was straight forward to insert, with

a single pass of the placement system sufficient to insert the device in 11 (58%) cases. Placement was successful on a second pass in the remaining 8 (42%) cases. Seventeen (89%) devices remained in situ for the complete 1 hour time period; however, 2 (11%) did not reach the entire time requirement (range, 22 to 40 minutes). In 1 case the device was inadvertently moved during FESS procedure by standard tools and became dislodged. The device was retrieved from the nasal cavity causing no adverse events. In a second case the device was removed by the surgeon to enable better visualization for other FESS procedures. Those devices that did not remain in the MSO for 60 minutes were excluded from further evaluation and an uuncinectomy was performed. The insertion devices expanded to a mean of  $4.8 \pm 0.5$  mm. The MSO was observed to remain the same size as the removed device although it was not possible to measure the MSO size accurately due to the intact uuncinate. No adverse events were recorded during device removal.

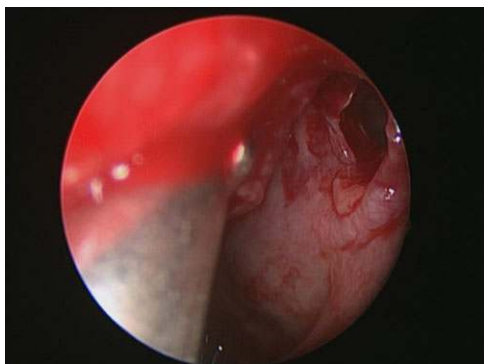
MSO patency was evaluated immediately after device removal and at 7, 30, and 90 days (Table 2). After removal of the device, despite the uuncinate still being intact, it was possible to visualize most of the MSO endoscopically, unlike the situation preoperatively. Immediately after removal of the device (Fig. 7), 16 of 17 (94%) MSO were visibly patent and 1 of 17 (6%) could not be visualized endoscopically to confirm patency (indeterminate). At 7 days postinsertion, 12 of 15 (80%) MSO were seen to be patent and 3 of 15 (16%) were indeterminate. One individual (2 ostia) was withdrawn from the study by the lead investigator as they were unable to comply with the study follow-up; they were therefore removed from further study-related evaluation. At 30 days postinsertion, 13 of 15 (87%) MSO were visibly patent, 2 (13%) were indeterminate. At 90 days postinsertion, 14 of 15 (93%) MSO were visibly patent and 1 (7%) was indeterminate (Fig. 8). No MSOs were noted to be nonpatent on endoscopic assessment.

There were no specific device related adverse events recorded in the postoperative period. Other adverse events recorded related to FESS, and not specific to device use, included facial pain reported at 7 days among 2 of 11 (18%) subjects and headaches reported by 2 of 11 (18%) individuals at 7 days and 2 (18%) subjects at 30 days. Active bleeding was reported by 3 (27%) individuals at 7 days and 1 (9%) at 30 days postsurgery. One individual (9%) reported a sinus infection at 90 days postsurgery. Topical budesonide to treat postoperative edema was prescribed

**TABLE 2.** Intraoperative and postoperative patency

Subject	MSO treated	Intraoperative (after device removal)	7-day follow-up	30-day follow-up	90-day follow-up
1A	Right	Patent	Withdraw	Withdraw	Withdraw
1B	Left	Patent	Withdraw	Withdraw	Withdraw
2	Left	Patent	Patent	Patent	Patent
3A	Right	Patent	No visual	No visual	No visual
3B	Left	Patent	Patent	Patent	Patent
4A	Right	Patent	Patent	Patent	Patent
4B	Left	Patent	Patent	Patent	Patent
5A	Right	Patent	Patent	Patent	Patent
5B	Left	Patent	Patent	Patent	Patent
6	Right	Patent	Patent	Patent	Patent
7A	Right	Patent	Patent	Patent	Patent
7B	Left	Device dislodged	N/A	N/A	N/A
8A	Right	Device removed	N/A	N/A	N/A
8B	Left	Patent	Patent	Patent	Patent
9A	Right	Patent	No visual	Patent	Patent
9B	Left	No visual	No visual	No visual	Patent
10	Right	Patent	Patent	Patent	Patent
11	Right	Patent	Patent	Patent	Patent
12	Left	Patent	Patent	Patent	Patent

MSO = maxillary sinus ostium; N/A = not applicable.

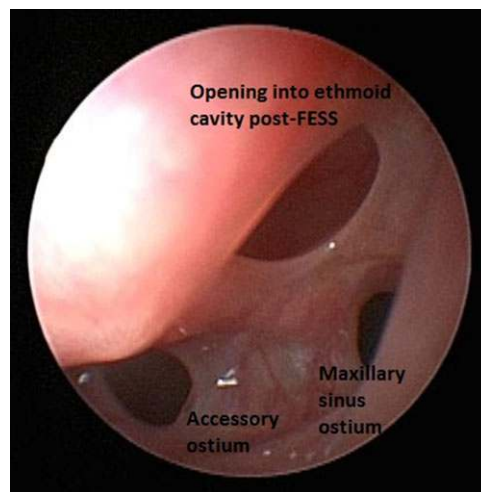


**FIGURE 7.** Ostia immediately postremoval of device.

for 5 (45%) individuals. One subject in the study group underwent revision frontal sinusotomy but there were no revisions of the maxillary sinus related to device use. Therefore, in total, none of 15 (0%) MSOs required revision surgery.

### Discussion

Balloon technology in the sinuses was first introduced in 2005, and developed from the success of balloon use in other specialties. The surrounding mucosa is compressed



**FIGURE 8.** Three months postremoval of dilation device (different patient from Fig. 7).

by the balloon and causes microfracture of the circumferential bone.<sup>5,6</sup> It has been argued that balloon dilation may enhance mucosal preservation, reduce local trauma, and restore the natural sinus drainage pathways resulting in effective relief of symptoms. There have been many studies looking into the feasibility, safety and efficacy of balloon dilation of sinus ostia to treat CRS. Initially, a cadaveric model was used to establish the feasibility and safety of the device.<sup>11</sup> Following this study it was concluded that balloon use was feasible and may cause less mucosal trauma than the standard endoscopic surgical techniques. The first human study involving 10 FESS patients was performed by Brown and Bolger.<sup>12</sup> All planned sinus ostia were successfully dilated (10 maxillary, 5 sphenoid, 3 frontal) with no adverse events reported. The first multicentre trial was the Clinical Evaluation to Confirm Safety and Efficacy of Sinuplasty in the Paranasal Sinuses (CLEAR) study.<sup>6</sup> At 12 weeks, confirmed patency for the maxillary sinus was 84%, 3% nonpatent, and 13% not able to visualize, compared to 93% patent, 0% nonpatent, and 7% unable to visualize in our study. Patient symptom scores in the CLEAR study (20-item Sinonasal Outcomes Test [SNOT-20]) also significantly improved from baseline. This cohort of patients was then followed up at 1 and 2 years.<sup>7,8</sup> Both studies demonstrated that significant improvements were maintained in Lund-Mackay CT scores and symptom scores (SNOT 20). There are very few comparative studies using balloon technology; however, Plaza et al.<sup>13</sup> published the first randomized controlled clinical trial using balloon dilation of the frontal recess as part of a hybrid procedure in patients with CRS with nasal polyposis (CRSwNP). At 12 months following surgery they demonstrated a statistically significant reduction in Lund-Mackay stage in general and specifically related to the frontal sinus. The patency of the frontal recess seen by office endoscopy was statistically more frequent after balloon treatment (75% vs 63%).

The maxillary sinus ostium self-dilation device used in this study has the benefits of a standard balloon, but since

the device dilates slowly and at lower pressure over a set period of time, the mucosal trauma and resulting scarring may potentially be reduced even further. This is the first human study using this device, and it demonstrates that it is feasible to place the dilation device into the MSO under endoscopic guidance (100% successful placement). This compares well with standard balloon dilation studies. The device was easy to insert with successful placement in all cases with at the most 2 passes of the placement system required. Again, in our experience, this compares favorably to balloon devices. The device remained in place the requisite time period to achieve dilation in 89% of MSOs. In 2 MSOs (11%) the device was dislodged or removed to allow better visualization for additional FESS procedures. The device could be placed at the end of FESS in the operating room and removed in recovery, thus alleviating the issues with device displacement during the procedure.


The device dilated in all cases when it was successfully placed and remained in situ for the full hour. There were no significant adverse events recorded during device placement or removal. It appears, therefore, that placement of this osmotic self-dilating expansion device in human MSO is safe, achievable and effective at dilating the ostia. At 3 months the sinus ostia appear to remain patent although longer-term follow-up is required. The revision rate of the maxillary sinus was 0% (0/15). This revision rate is lower than that of FESS<sup>14</sup> and that of balloon dilation.<sup>6–8, 15</sup> However, the numbers in this pilot study are small and follow-up relatively short, so it is not possible to determine an accurate revision rate. Further studies will be required to address this.

The use of any dilation device has the potential to inadvertently create a false lumen or cannulate an existing accessory ostia. It is unclear what the clinical impact on patient outcomes is in these situations. It is possible that secondary drainage pathways, whether preexisting or created, result in mucus recirculation. However, not all secondary pathways result in recirculation, and not all patients with recirculation are symptomatic.<sup>16</sup> In our study there was no evidence of any false lumens being created or accessory ostia being cannulated.

The study has limitations. There was no assessment of patient reported outcomes to assess the effectiveness of the

device in improving symptoms. This is mainly due to the fact that as well as the device being placed, other FESS procedures such as ethmoidectomy were performed, and so it would not be possible to attribute any improvement in scores to the device dilating the MSO. Also, although attempts were made to assess and compare the MSO endoscopically preoperatively and postoperatively, there was no measurement of MSO size. This was not possible due to the presence of an intact uncinate. Other studies looking at balloon dilation of the MSO have noted similar problems with measuring ostial size and used patency as their main outcome measure. Establishing MSO patency endoscopically has also been recognized as being difficult in these studies due to increased preservation of tissue using balloon dilation, such as an intact uncinate.<sup>6</sup> Therefore, in our study device size at removal was used as a surrogate for MSO size. The MSO were confirmed either patent or not patent under direct vision endoscopically postoperatively. Again due to the intact uncinate there were MSO that could not be confirmed patent. However, in no cases were the MSO observed to be obstructed. In addition, the follow-up period was only 3 months and therefore was not designed to evaluate long-term outcomes in terms of patency and revision rates. However, the study was designed to address the feasibility of placement and removal of the device, as well as its functionality, with the primary objective of assessing the safety and performance of the system for dilation of the MSO. Further studies are now required to compare the device with other techniques, such as balloon dilation and traditional FESS, and to clearly demonstrate longer-term outcomes and effectiveness now that the safety and feasibility of the device has been established. There are currently ongoing studies designed to assess the longer-term effectiveness of the dilation device.

## Conclusion

Placement of a novel osmotic self-dilating expansion device in human MSO is safe, achievable, and effective at dilating the ostia. Further clinical studies are required to investigate the clinical effectiveness and long-term outcomes of the device, as well as trials looking into its placement under local anesthetic in the office, which are already underway. 

## References

- Adams PF, Hendershot GE, Marano MA. Centers for Disease Control and Prevention/National Center for Health Statistics. Current estimates from the National Health Interview Survey, 1996. *Vital Health Stat.* 1999;10(200):1–203.
- Blackwell DL, Collins JG, Coles R. Summary health statistics for U.S. adults: National Health Interview Survey, 1997. *Vital Health Stat.* 2002;10(205):1–109.
- Fokkens W, Lund V, Mullol J. European Position Paper on Rhinosinusitis and Nasal Polyps group. European Position Paper on Rhinosinusitis and Nasal Polyps 2007. *Rhinol Suppl.* 2007;(20):1–136.
- Albu S, Tomescu E. Small and large middle meatus antrostomies in the treatment of chronic maxillary sinusitis. *Otolaryngol Head Neck Surg.* 2004;131:542–547.
- Vaughan WC. Review of balloon sinuplasty. *Curr Opin Otolaryngol Head Neck Surg.* 2008;16:2–9.
- Bolger WE, Brown CL, Church CA, et al. Safety and outcomes of balloon catheter sinusotomy: a multicenter 24-week analysis in 115 patients. *Otolaryngol Head Neck Surg.* 2007;137:10–20.
- Kuhn FA, Church CA, Goldberg AN, Levine HL, Sillers MJ, Vaughan WC, Weiss RL. Balloon catheter sinusotomy: one-year follow-up-outcomes and role in functional endoscopic sinus surgery. *Otolaryngol Head Neck Surg.* 2008;139(3 Suppl 3):S27–S37.
- Weiss RL, Church CA, Kuhn FA, Levine HL, Sillers MJ, Vaughan WC. Long-term outcome analysis of balloon catheter sinusotomy: two-year follow-up. *Otolaryngol Head Neck Surg.* 2008;139(3 Suppl 3):S38–S46.
- Stankiewicz J, Tami T, Truitt T, Atkins J, Liepert D, Winegar B. Transantral, endoscopically guided balloon dilatation of the ostiomeatal complex for chronic rhinosinusitis under local anesthesia. *Am J Rhinol Allergy.* 2009;23:321–327.
- Hester J, Edgren D, Koreck A, Fox J, Mandrusov J. Assessment of the short term patency of the maxillary sinus ostium following dilatation with an osmotic device in a sheep model. Poster presented at: Annual Meeting of the American Rhinologic Society. *Poster* 2012:P–7.
- Bolger WE, Vaughan WC. Catheter-based dilation of the sinus ostia: initial safety and feasibility analysis in a cadaver model. *Am J Rhinol.* 2006;20:290–294.
- Brown CL, Bolger WE. Safety and feasibility of balloon catheter dilation of paranasal sinus ostia: a

- preliminary investigation. *Ann Otol Rhinol Laryngol*. 2006;115:293-299.
13. Plaza G, Eisenberg G, Montojo J, Onrubia T, Urbasos M, O'Connor C. Balloon dilation of the frontal recess: a randomized clinical trial. *Ann Otol Rhinol Laryngol*. 2011;120:511-518.
  14. Hopkins C, Slack R, Lund V, Brown P, Copley L, Browne J. Long-term outcomes from the English national comparative audit of surgery for nasal polyposis and chronic rhinosinusitis. *Laryngoscope* 2009;119:2459-2465.
  15. Levine HL, Sertich AP 2nd, Hoisington DR, Weiss RL, Pritikin J. Multicenter registry of balloon catheter sinusotomy outcomes for 1,036 patients. *Ann Otol Rhinol Laryngol*. 2008;117:263-270.
  16. Mann WJ, Tóth M, Gouveris H, Amedee RG. The drainage system of the paranasal sinuses: a review with possible implications for balloon catheter dilation. *Am J Rhinol Allergy*. 2011;25:245-248.